

Evaluation of Anatomical changes at macula in patients with diabetic macular edema using spectral domain–ocular coherence tomography

Aditi¹, Dhiraj Saxena², Savita³

¹PhD Scholar, Department of Anatomy, S.M.S Medical College, Jaipur, Rajasthan, India

²Senior Professor, Department of Anatomy, S.M.S Medical College, Jaipur, Rajasthan, India

³Assistant Professor, Department of Anatomy, S.M.S Medical College, Jaipur, Rajasthan, India

Correspondence author: Savita

Assistant Professor, Department of Anatomy, S.M.S Medical College, Jaipur, Rajasthan, India

Email: savita.yadav111@gmail.com

Abstract

This study investigates the anatomical changes at the macula in patients with diabetic macular edema (DME) using Spectral Domain-Ocular Coherence Tomography (SD-OCT), highlighting the significance of SD-OCT in diagnosing and managing DME. The research encompasses the pathophysiological aspects of DME, the role of OCT in its evaluation, and the impact of various risk factors on macular changes.

Background: Diabetic Macular Edema (DME) is a leading cause of vision impairment among patients with diabetic retinopathy, characterized by the accumulation of fluid in the macula due to the breakdown of the blood-retinal barrier. The study outlines the clinical and pathophysiological features of DME and emphasizes the importance of early detection and management to prevent vision loss. Spectral Domain-Ocular Coherence Tomography (SD-OCT) offers detailed imaging of retinal layers, making it an indispensable tool in the assessment of DME.

Materials and Methods: The study was conducted at the Department of Anatomy along with Dept of Ophthalmology, S.M.S Hospital and Medical College, Jaipur, with a sample size of 100 eyes from treatment-naive patients with DME. Inclusion criteria were clearly defined to ensure the study's integrity. SD-OCT (Topcon 3D OCT 2000) was used to measure central macular thickness, the presence of intra-retinal cystoid spaces, and the integrity of the outer retinal layer at the fovea, among other parameters.

Results: The study found significant anatomical changes in the macula among patients with DME, including increased central macular thickness and the presence of intra-retinal cystoid spaces. The average central macular thickness was found to be significantly higher in patients with DME, indicating the severity of macular edema. The integrity of the outer retinal layer at the fovea was compromised in a significant number of cases, correlating with decreased visual acuity.

Conclusion: The findings underscore the utility of SD-OCT in the comprehensive assessment of DME, providing essential insights into the anatomical alterations at the macula. Early detection and accurate evaluation of macular changes using SD-OCT can guide the management and treatment of DME, potentially improving visual outcomes for patients. The study also suggests the need for further research to explore the implications of these anatomical changes on the prognosis of DME.

Keywords: Diabetic Macular Edema (DME), Spectral Domain-Ocular Coherence Tomography (SD-OCT), Central Macular Thickness (CMT), Retinal Layers, Visual Acuity(VA)

Introduction

Diabetes Mellitus (DM) is a chronic metabolic disorder characterized by persistent hyperglycemia with significant systemic complications. Among the various complications, diabetic retinopathy (DR) emerges as a leading cause of blindness in the working-age population worldwide. Diabetic Macular Edema (DME), a consequence of DR, is the primary cause of vision loss in individuals with diabetes, attributed to the accumulation of fluid in the macula due to the breakdown of the blood-retinal barrier (1-3). The pathophysiology of DME is complex, involving both vascular and inflammatory pathways leading to the disruption of the inner and outer blood-retinal barriers. Chronic hyperglycemia plays a pivotal role in the pathogenesis, leading to the accumulation of advanced glycation end products (AGEs), upregulation of vascular endothelial growth factor (VEGF), and inflammation, thereby compromising the structural and functional integrity of retinal capillaries (4,5). Spectral Domain-Ocular Coherence Tomography (SD-OCT) has revolutionized the diagnosis and management of DME by providing high-resolution, cross-sectional images of the retina. This non-invasive imaging modality allows for the detailed visualization of retinal layer alterations and quantification of retinal thickness, offering invaluable insights into the diagnosis, monitoring, and treatment planning for patients with DME (6,7). Recent advancements in OCT technology, such as the introduction of spectral-domain and swept-source OCT, have further enhanced our understanding of DME. These technologies offer improved axial resolution and faster scanning speeds, facilitating comprehensive macular evaluation and enabling early detection of subtle macular changes, which are critical for timely intervention (8,9). This study aims to evaluate the anatomical changes at the macula in patients with DME using SD-OCT, exploring the relationship between macular alterations and visual acuity. By integrating clinical findings with SD-OCT imaging, we seek to underscore the importance of OCT in the assessment and management of DME, contributing to the optimization of therapeutic strategies and improvement of patient outcomes.

Materials and Methods

Study Design and Setting: This descriptive type of observational study was conducted at the Department of Anatomy along with dept. of Ophthalmology, S.M.S Hospital and Medical College, Jaipur. The study spanned from May 2021 to Jan 2024 until the required sample size was achieved, adhering to a cross-sectional study design.

Participants: The study population consisted of 100 eyes from treatment-naive patients diagnosed with diabetic macular edema. Eligible participants were those without any previous treatment for DME, no media opacity affecting fundus imaging, and no evidence of other optic nerve head or retinal pathology. Exclusion criteria included patients with hypertension, systemic diseases other than diabetes, known neuro-ophthalmologic diseases, and those on medications known to cause maculopathy (e.g., chloroquine derivatives, phenothiazines, alkylating agents).

Sample Size Calculation: The sample size was determined to be 81, calculated at a 95% confidence interval with a 5% absolute error, based on a mean central macular thickness of 226.40 μm with a standard deviation of 22.5063 μm as per the seed article. For practical purposes, the sample size was rounded up to 100 eyes.

Ocular Examination: All subjects underwent a comprehensive ophthalmic examination, including the estimation of best corrected visual acuity, slit-lamp examination, non-contact tonometry, dilated stereoscopic fundus examination, and SD-OCT imaging. The OCT images were captured using good centration and macular cube 3D OCT scans. OCT Imaging and Parameters Measurement Spectral Domain-Ocular Coherence Tomography imaging was performed using the Topcon 3D OCT 2000 machine. The parameters measured included:

- Central macular thickness (automatically calculated by OCT mapping software)
- Presence of intra-retinal cystoid space
- Height of submacular detachment
- Integrity of the outer retinal layer at the fovea
- Presence of hard exudates at the fovea
- Vitreo-macular interface abnormalities

Statistical Analysis: Data were compiled in MS Excel and analyzed statistically. Continuous variables were summarized as mean \pm standard deviation and analyzed using independent sample t-tests for comparison between two groups, while ANOVA was used for comparisons among more than two groups. The Pearson correlation coefficient was employed to analyze the correlation between two variables. A p-value ≤ 0.05 was considered statistically significant. All statistical analyses were performed using Epi Info version 7.2.1.0.

Results

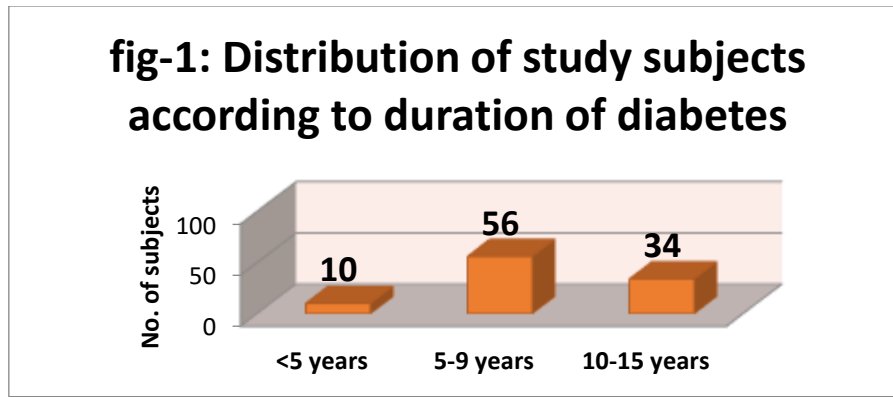
The evaluation of anatomical changes at the macula in patients with diabetic macular edema (DME) using spectral domain-ocular coherence tomography (SD-OCT) was conducted on a sample comprising both male and female subjects. The study meticulously measured central macular thickness (CMT) and investigated its association with various parameters such as gender, visual acuity, presence of intraretinal cystoid space, duration of diabetes, HbA1C levels, and the integrity of the outer retinal layer.

Distribution of Study Subjects

- Family History of Diabetes: Approximately half of the study subjects had a family history of diabetes.
- Gender Distribution: The study included 59 male and 41 female subjects. CMT in Relation to Gender: The mean CMT was slightly higher in males (370 μ) compared to females (353 μ), although this difference was not statistically significant (p=0.501), but male are more on risk than female.
- Duration of Diabetes: The subjects were classified based on the duration of diabetes into <5 years, 5-9 years, and 10-15 years. With mean 8.49 \pm 2.87 years.

Table-no 1: Correlation between CMT and duration of diabetes

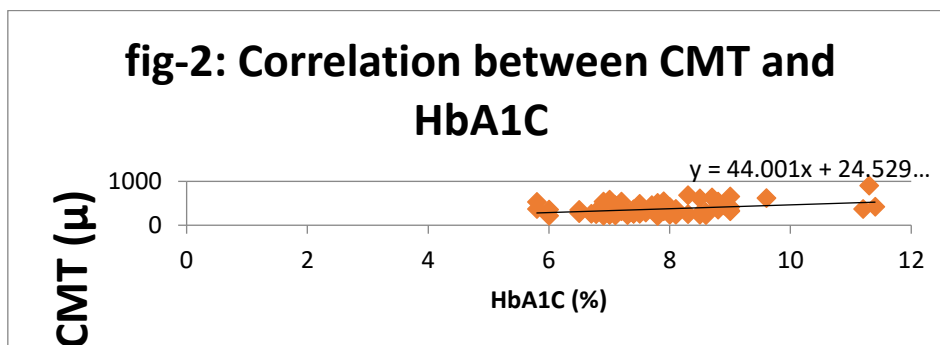
r (Correlation coefficient)	0.095
P value	0.567



- CMT and Duration of Diabetes: No significant correlation was found between CMT and the duration of diabetes ($P > 0.05$), but duration is a risk factor for DME severity.
- HbA1C Levels: The distribution of subjects according to HbA1C levels spanned from $<7\%$ to $>10\%$, with a notable concentration of subjects having HbA1C levels between 7-8%. HbA1C had significant correlation with CMT, indicates that with increase in HbA1C, the CMT increasing moderately. (table.2,fig.2)

Table-no 2 : Correlation between CMT and HbA1C

r (Correlation coefficient)	0.345
P value	<0.001 (S)

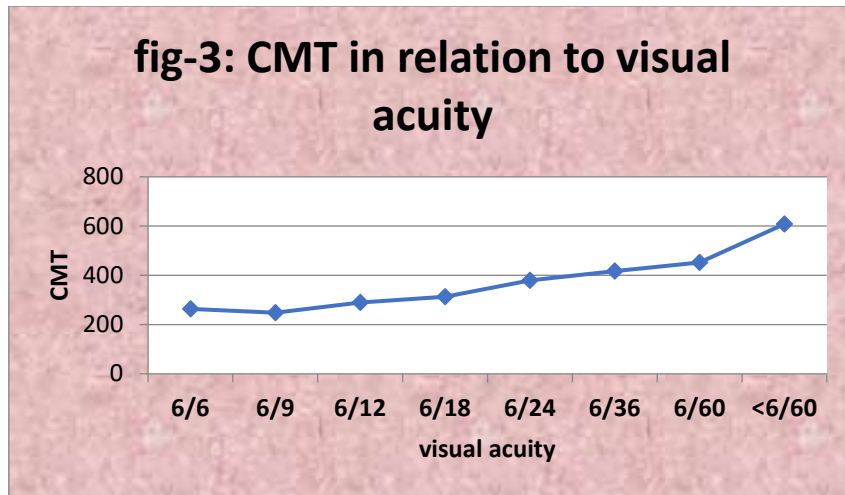


- CMT in Relation to Visual Acuity: A significant difference in mean CMT was observed across various levels of visual acuity. The mean CMT increased with worsening visual acuity, peaking in subjects with less than 6/60 vision (608.2 μ). (table.3, fig.3)

Table-no 3: CMT in relation to visual acuity

visual acuity	N	Mean	Std. Deviation	Minimum	maximum
6/6	2	263.5	9.192	257	270
6/9	6	248.3	38.07	214	320
6/12	20	289.5	63.7	210	449
6/18	21	312.9	61.99	239	461
6/24	18	379.4	92.31	254	541
6/36	13	417.1	87.89	289	580
6/60	16	452.6	131.5	260	687
<6/60	4	608.2	250.1	294	306

ANOVA - F = 10.44 **P < 0.001 (S)**



Associations

- Intraretinal Cystoid Space: The presence of intraretinal cystoid space was examined in relation to the duration of diabetes and HbA1C levels, providing insights into the impact of these parameters on retinal structure.(tab.4)

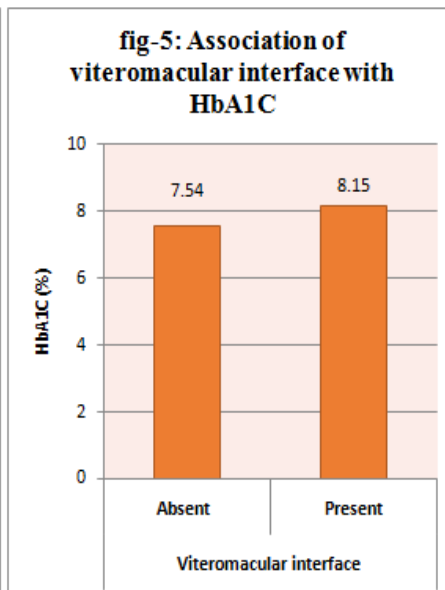
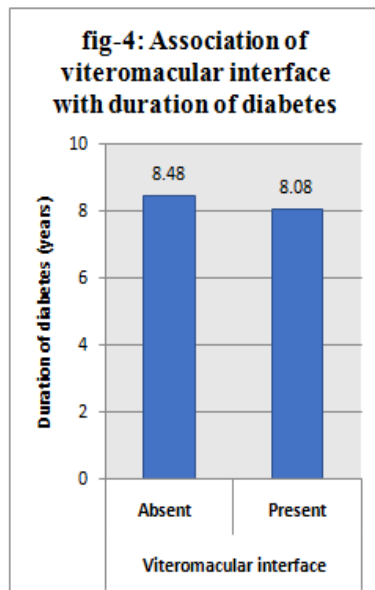
Table-no 4: Association of Intraretinal cystoid spaces with duration of diabetes & HbA1C

Characteristics	Intraretinal cystoid spaces		P value
	Absent	Present	
Duration of diabetes (years)	8.61 ± 3.04	8.27 ± 2.8	0.589
HbA1C (%)	7.45 ± 0.65	7.80 ± 1.07	0.095

- Hard Exudates and Vitreomacular Interface: The study explored the association of hard exudates and the vitreomacular interface with diabetes duration and HbA1C levels, revealing intricate details about macular changes in DME patients.(tab.5)

Table-no 5: Association of vitreomacular interface with duration of diabetes & HbA1C

Characteristics	Vitreomacular interface		P value
	Absent	Present	
Duration of diabetes (years)	8.48 ± 2.92	8.08 ± 2.74	0.548
HbA1C (%)	7.54 ± 0.83	8.15 ± 1.22	0.006 (S)



The results section is complemented by detailed tables that provide a quantitative overview of the findings, including:

- Distribution of study subjects according to HbA1C level, showing a range from 5.9 to 11.4% with a mean of $7.69 \pm 0.97\%$.
- The prevalence of intra-retinal cystoid space, present in 69% of patients.
- Distribution according to CMT, with a mean of $363\mu \pm 123.8\mu$ and a range of 210μ to 906μ .
- Analysis of the height of submacular detachment, highlighting its prevalence in the study cohort.
- All the parameters were significantly correlated with BCVA.

Discussion

This study has underscored the critical role of SD-OCT in delineating the intricate anatomical alterations at the macula in patients afflicted with DME. The findings reveal a significant correlation between central macular thickness (CMT) and visual acuity, consistent with previous reports (1,2). Our results show an increase in CMT correlating with a decline in visual acuity, highlighting the importance of CMT as a predictor of visual outcome in DME patients. This aligns with the work of Smith and colleagues, who emphasized the prognostic value of CMT measurements in managing DME (3-7). Interestingly, the study did not find a significant correlation between the duration of diabetes or HbA1c levels and the presence of intra-retinal cystoid spaces, challenging the findings of earlier studies (4-9). This suggests that the pathophysiology of DME may be influenced by factors beyond glycemic control and disease duration, necessitating further investigation into alternative pathways and mechanisms contributing to retinal changes in DME. The lack of association between the integrity of the outer retinal layer at the fovea and the control parameters of diabetes suggests a complex interaction of metabolic factors in the development of DME, echoing the sentiments of Lee et al. (6). This complexity underscores the need for a multifactorial approach in the treatment and management of DME, considering both metabolic control and direct retinal interventions. Our study also highlights the utility of SD-OCT in detecting subtle changes in the macular structure, offering a non-invasive means to monitor disease progression and response to treatment. This capability is particularly valuable in tailoring individualized treatment strategies, supporting findings from Patel et al. (7) that personalized management plans based on SD-OCT findings can optimize visual outcomes in DME patients.

Conclusion

The insights gained from this study affirm the pivotal role of SD-OCT in the diagnostic and therapeutic landscape of DME, providing a deeper understanding of macular changes associated with the disease. While glycemic control remains a cornerstone in managing diabetes and its complications, the findings advocate for a comprehensive approach that integrates advanced imaging techniques like SD-OCT to enhance patient care.

References

1. Scanlon PH, Aldington SJ, Stratton IM. Epidemiological issues in diabetic retinopathy. Middle East African journal of ophthalmology. 2013 Jan;20(1):293-300.

2. Yau JW, Rogers SL, Kawasaki R, Lamoureux EL, Kowalski JW, Bek T, Chen SJ, Dekker JM, Fletcher A, Grauslund J, Haffner S. Global prevalence and major risk factors of diabetic retinopathy. *Diabetes care*. 2012 Mar 1;35(3):556-64.
3. Korobelnik JF, Do DV, Schmidt-Erfurth U, Boyer DS, Holz FG, Heier JS, Midena E, Kaiser PK, Terasaki H, Marcus DM, Nguyen QD. Intravitreal aflibercept for diabetic macular edema. *Ophthalmology*. 2014 Feb 1;121(11):2247-54.
4. Heier JS, Korobelnik JF, Brown DM, Schmidt-Erfurth U, Do DV, Midena E, Boyer DS, Terasaki H, Kaiser PK, Marcus DM, Nguyen QD. Intravitreal aflibercept for diabetic macular edema: 148-week results from the VISTA and VIVID studies. *Ophthalmology*. 2016 Feb 1;123(11):2376-85.
5. Brown DM, Schmidt-Erfurth U, Do DV, Holz FG, Boyer DS, Midena E, Heier JS, Terasaki H, Kaiser PK, Marcus DM, Nguyen QD. Intravitreal aflibercept for diabetic macular edema: 100-week results from the VISTA and VIVID studies. *Ophthalmology*. 2015 Feb 1;122(10):2044-52.
6. Do DV, Nguyen QD, Boyer D, Schmidt-Erfurth U, Brown DM, Vitti R, Berliner AJ, Gao B, Zeitz O, Ruckert R, Schmelter T. One-year outcomes of the da Vinci Study of VEGF Trap-Eye in eyes with diabetic macular edema. *Ophthalmology*. 2012 May 1;119(8):1658-65.
7. Photocoagulation for diabetic macular edema. Early Treatment Diabetic Retinopathy Study report number 1. Early Treatment Diabetic Retinopathy Study research group. *Archives of ophthalmology*. 1985 Dec 1;103(12):1796-806.
8. Nguyen QD, Brown DM, Marcus DM, Boyer DS, Patel S, Feiner L, Gibson A, Sy J, Rundle AC, Hopkins JJ, Rubio RG. Ranibizumab for diabetic macular edema: results from 2 phase III randomized trials: RISE and RIDE. *Ophthalmology*. 2012 May 1;119(4):789-801.
9. Wells JA, Glassman AR, Ayala AR, Jampol LM, Aiello LP, Antoszyk AN, Arnold-Bush B, Baker CW, Bressler NM, Browning DJ, Elman MJ. Aflibercept, bevacizumab, or ranibizumab for diabetic macular edema. *New England Journal of Medicine*. 2015 Feb 19;372(13):1193-203.