

## Extraskelatal Variant Of Osteosarcoma Of Breast-A Rare Case Report.

<sup>1</sup>Dr. Suman Chandra Das, <sup>2</sup>Dr. Ashish Kr Gupta, <sup>3</sup>Dr. Rakesh Tripura

<sup>1</sup>Fellow Trainee, Department of Surgical Oncology, ABV Regional Cancer Center, Agartala, Tripura

<sup>2</sup>Associate Professor, Department of Surgical Oncology, ABV Regional Cancer Center, Agartala, Tripura

<sup>3</sup>Fellow Trainee, Department of Surgical Oncology, ABV Regional Cancer Center, Agartala, Tripura

**Corresponding Author: Dr. Suman Chandra Das**

Fellow Trainee, Department of Surgical Oncology, ABV Regional Cancer Center, Agartala, Tripura

### Abstract:

#### Introduction:

Primary osteosarcoma of breast is a very rare soft tissue form of osteosarcoma without involvement of skeletal system. It's a heterogeneous neoplasms derived from nonepithelial elements of glands, & they represent less than 1% breast cancers & less than 5% of all sarcomas. (1)

Primary osteosarcoma of the breast is a very rare and aggressive neoplasm. Approximately, 150 cases of this pathology have been reported in the literature since 1957.(2,3)

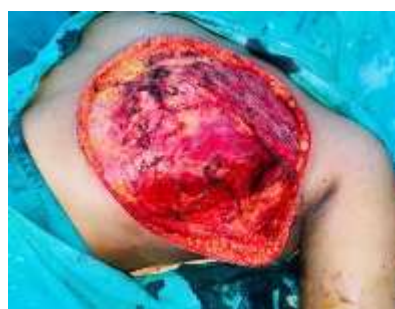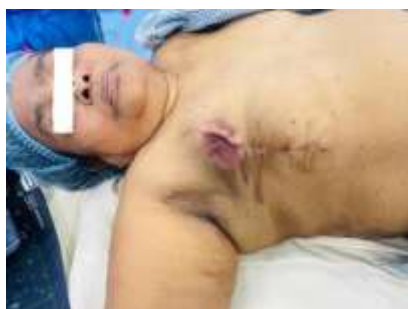In contrast to skeletal osteosarcoma affecting mainly young patients, primary osteosarcoma of the breast occurs in older patients, with a mean age at presentation around 65.(4)

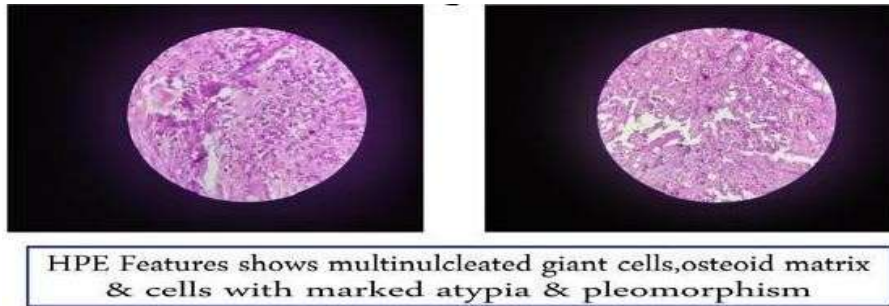
Because of rarity of disease, both clinical features & optimal treatment are still to be defined. Although there are other case reports concerning primary osteosarcoma of the breast, we believe that each case can contribute to improve the management of rare case.

**Materials & Methods:** A 64 year old post simple mastectomy female patient reported to our dept. with recurrence of lump on residual breast tissue right side. Staging CT scan & skeletal scintigraphy showed no evidence of metastastic disease. History reveals patient had a lump in right breast from last 6 months. Earlier FNAC (Fine Needle Aspiration Cytology) was done which came as nonspecific sarcoma after that simple mastectomy was performed. Biopsy report reveals positive margins in relation to deep revised margin (DRM) & one of the peripheral revised margin (PRM) & recurrence of lump on residual breast tissue right side with diagnosis of osteosarcoma of right breast.

**Results:** We performed Redo Mastectomy in our institution with revision of all involved margins & sent for biopsy. Biopsy report reveals clear margins all around with previous diagnosis of osteosarcoma of right breast. Patient is disease free from past 2 months follow up.

HPE Features shows multinucleated giant cells, osteoid matrix & cells with marked atypia & pleomorphism



**Discussion:**

Extra-skeletal osteosarcomas are uncommon. The majority arise in the soft tissue of lower extremity<sup>(5)</sup>. Their origin in a number of parenchymal organs has been documented. Mammary sarcomas are rare, representing less than 1% of all primary breast malignancies.<sup>(6)</sup>

In comparison, bone producing spindle cell neoplasms with an epithelial origin, so called metaplastic (sarcomatoid) carcinomas, are more common.<sup>(7)</sup>

POB is considered a disease of middle and old age in comparison to the younger age group of patients with skeletal osteosarcoma.

**Conclusion:** Primary osteosarcoma of breast is rare & aggressive lesion with blood born spread more common than lymphatic spread. For this reason lymphatic axillary dissection is not considered as a mainstay of surgical treatment. Mastectomy appears to be most adapted primary treatment for this tumor & the use of an adjuvant therapy still requires further investigations. Due to aggressivity and the the rarity of the disease, it seems to be important to systematically follow up the patient in order to appropriately to manage such patients suffering from this disease.

**REFERENCES**

1. Voutsadakis IA, Zaman K, Leyvraz S. Breast sarcomas: current and future perspectives. *Breast*. 2011;20(3):199–204. doi: 10.1016/j.breast.2011.02.016. [DOI]
2. Khan, S. , Griffiths E., Shah N., and Ravi S.. 2008. Primary osteogenic sarcoma of the breast: a case report. *Cases J*. 1:148. 1–4. [DOI]
3. Silver, S. A. , and Tavassoli F. A.. 1998. Primary osteogenic sarcoma of the breast: a clinicopathologic analysis of 50 cases. *Am. J. Surg. Pathol*. 8:925–933. [DOI]
4. Vorobiof G, Hariparsad G, Freinkel W, Said H, Vorobiof DA. Primary osteosarcoma of the breast: a case report. *Breast Journal*. 2003;9(3):231–233. doi: 10.1046/j.1524-4741.2003.09320.x. [DOI]
5. Chung EB, Enzinger FM. Extraskelatal osteosarcoma. *Cancer* 1987;60:1132–42 [DOI]
6. Barnes L, Pietruszka M. Sarcomas of the breast: a clinicopathologic analysis of ten cases. *Cancer* 1977;40:1577–85 [DOI]
7. Bahrami A, Ressetkova E, Ro J, et al. Primary osteosarcoma of the breast: report of 2 cases. *Arch Pathol Lab Med* 2007;131:792–5 [DOI]