

“A STUDY OF HISTOMORPHOLOGICAL SPECTRUM OF BREAST LESIONS IN A TERTIARY CARE HOSPITAL”

DR. JIGISHA MER¹ & DR. BHUMIKA PADHIYAR²

^{1,2}SENIOR RESIDENTS PATHOLOGY DEPARTMENT

GMERS MEDICAL COLLEGE, JUNAGADH, GUJARAT, INDIA.

CORRESPONDING AUTHOR: DR. JIGISHA MER

MOBILE NUMBER: 7600020576, 9978059281,

EMAIL ID: Jigimer1392@gmail.com

bhumikapadhiyar94@gmail.com

ABSTRACT

INTRODUCTION:

Breast tissue is a modified sweat gland, exhibits a wide spectrum of pathological lesions. The most common clinical feature of breast disease is a palpable lump. Benign breast lesions like fibroadenoma are more prevalent. Breast lump must be examined and evaluated by a surgeon to rule out malignancy. Histopathological examination along with radiological findings and clinical examination is important to diagnose the lesions and to determine the best treatment plan for the patient.

METHODOLOGY:

A retrospective cross-sectional study was conducted at department of Pathology, GMERS medical college and hospital, Junagadh over a period of two years from January 2023 to December 2024. The biopsy sample was taken from clinically suspected breast lesions and sent to histopathology laboratory in 10% formalin. Sample was fixed in 10% neutral buffered formalin and kept overnight. Paraffin wax blocks were made, sections taken, slides were dried and mounted with D.P.X. and seen under the microscope.

RESULT:

A total of 90 cases were studied over a period of two years from January 2023 to December 2024. Majority of the lesions were present in 21-30 years of age group. Benign tumors were the common lesions, in which fibroadenoma was the most common cause.

CONCLUSION:

Histopathology along with clinical examination and radiological findings plays an important role in early diagnosis of breast lesions.

KEY WORDS: Breast lesions, Histopathology, Fibroadenoma

MAIN TEXT:**INTRODUCTION:**

Breast tissue is a modified sweat gland and constantly under the varying influence of sex hormones, and it is one of the frequent sites of neoplasms in the human body. Breast tissue exhibits a wide spectrum of pathological lesions, usually presenting as palpable masses ranging from inflammatory, non-inflammatory, non-neoplastic and neoplastic lesions.^[1] The most common sign and symptom of breast diseases is a palpable mass or lump; although breast diseases can also present as inflammatory lesion, nipple secretion or imaging abnormalities.^[2] Benign breast lesions are more common than malignant, which is seen more commonly in age group of 20 to 40 years as opposed to malignant diseases, for which the incidence increases as the age advances.^[3] In spite of the fact that over 80% of breast lumps are benign, every breast lump must be examined and evaluated by a surgeon to rule out malignancy.^[4] A breast lump can be benign or malignant. So, the establishment of diagnosis preoperatively for correct management is of utmost importance. The investigation of palpable breast lumps in successful breast programmes utilizes a multidisciplinary approach that centres around the 'triple test', analysing clinical and radiologic findings in conjunction with the pathologic features.^{[5][6]} Histopathology plays an important role in the diagnosis of breast lesions. It is the main criteria that assess the adequacy of treatment and is a necessary component in the diagnosis, treatment, and prognosis of breast diseases.^[7]

AIM:

To study different types of breast lesions, their clinical presentation and histopathological features.

OBJECTIVES:

1. To classify the lesions according to their age and gender in breast lesions.
2. To describe their histopathological features.

METHODOLOGY:

1. Study design: Retrospective cross-sectional study
2. Study population: All patients who came at surgery OPD and advised excision biopsy (Lumpectomy) for suspected breast lesions at GMERS medical college and general hospital, Junagadh.
3. Study duration: 2 Years
4. Sample size: A total of 90 cases were studied.
 - Inclusion criteria: All patients who came with a history of breast lump in surgical department at GMERS medical college and general hospital, Junagadh from January 2023 to December 2024.

- Exclusion criteria: Female of prepubertal age group (<10 years).
5. Sampling method: Haematoxylin and eosin-stained slides of breast lesions were retrieved and reviewed. Clinical history and relevant data were acquired from the registers. All the slides were observed and findings were recorded.
- Specimens were sent in 10% formalin, twenty times that of the specimen volume. It was kept overnight in 10% formalin for proper fixation.
 - The excision biopsy specimen (Lumpectomy) received were examined grossly for their size, shape, colour and consistency. After passing the tissue dehydration, clearing and impregnation, embedding in paraffin were done.
 - Paraffin wax blocks were made and 3-4 micrometer sections were taken, slides were stained with H&E stain and mounted with D.P.X. and histology was studied under the microscope.
 - Results of histopathological findings were recorded along with age, sex, clinical features and site of lesions.
 - Data was entered in Microsoft Excel and descriptive data was obtained.

RESULT:

A total of 90 cases were studied from January 2023 to December 2024, out of which 82 (91.11%) were females and 8 (8.88%) were males. In present study, majority of cases were fall under 21-30 years of age group (37.77%). Gynecomastia is the enlargement of male breasts and it was observed in 8 (8.88%) cases. Breast lump (93.33%) was the most common complaint in our study. In 44 (48.88%) cases, breast lesions were found on the right side of breast followed by 42 (46.66%) cases on the left side and only 4 (4.44%) cases had bilateral lesions. Out of 90 cases, 64 cases (71.11%) were of benign origin, in which fibroadenoma (58.88%) was the most common cause.

Table 1: Age wise distribution of breast lesions:

Age	No. of cases	Percentage (%)
11-20	24	26.66
21-30	34	37.77
31-40	19	21.11
41-50	08	8.88
51-60	04	4.44
>60	01	1.11

Table 2: Gender wise distribution of breast lesions:

Gender	No. of cases	Percentage (%)
Female	82	91.11
Male	08	8.88

Figure 1: Pie chart for gender wise distribution of breast lesions

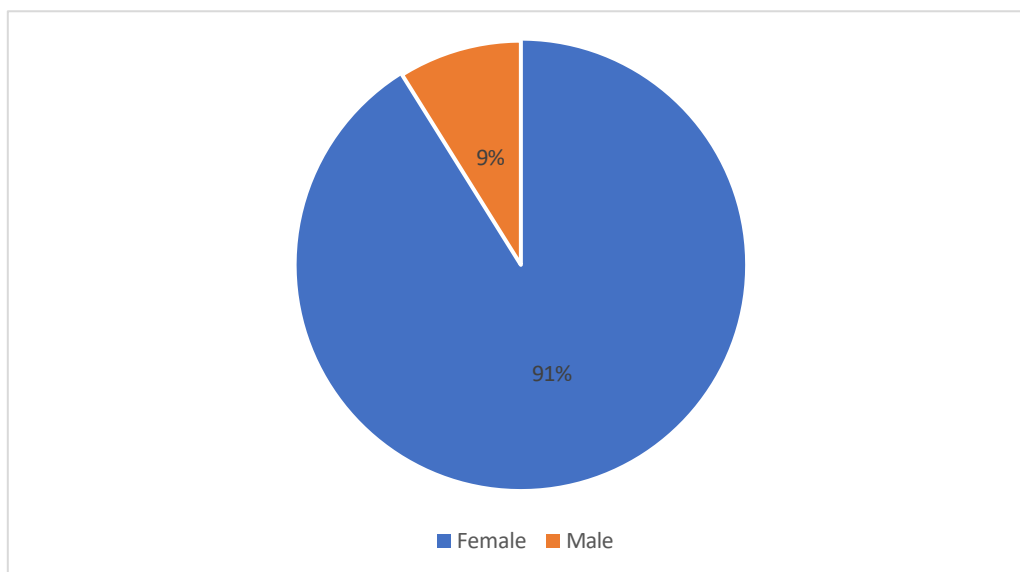


Table 3: Distribution of cases according to site of breast lesions:

Breast lesions	Left	Right	Bilateral	Total
Benign	33	29	02	64 (71.11%)
Malignant	03	06	00	09 (10%)
Non-neoplastic	02	06	01	09 (10%)
Lesions of male breast	04	03	01	08 (8.88%)
Total	42(46.66%)	44(48.88%)	04(4.44%)	90

Figure 2: Distribution of breast lesions according to site

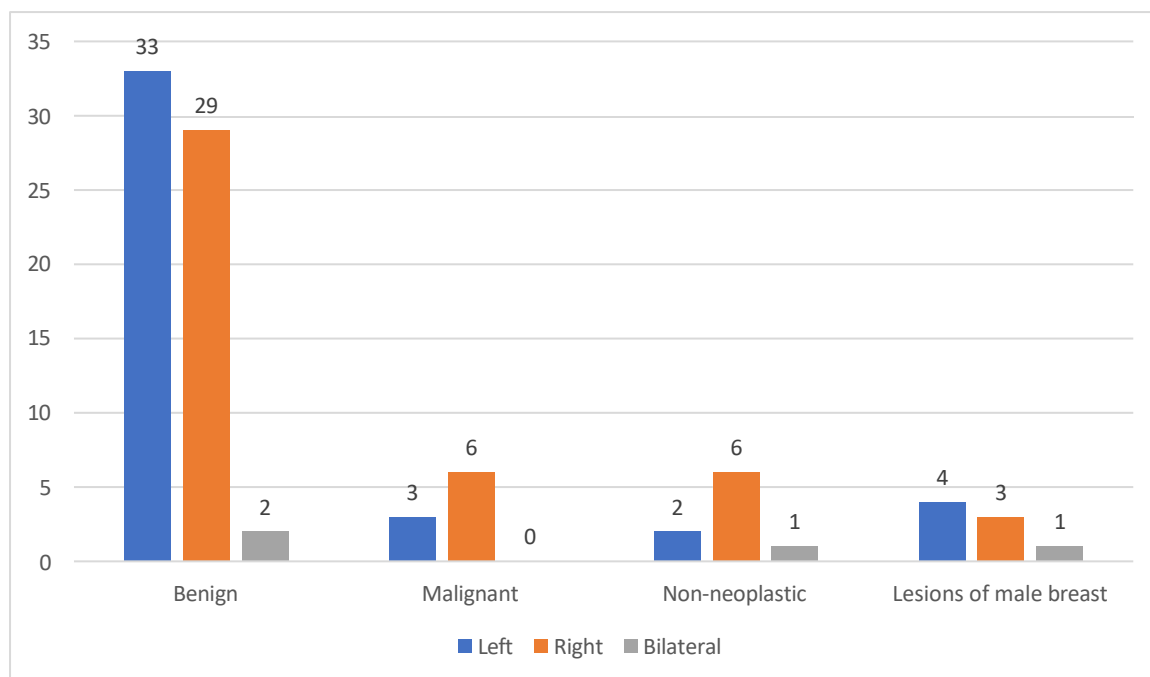


Table 4: Distribution of cases according to clinical features of breast lesions:

Clinical features	No. of cases	Percentage (%)
Breast lump only	84	93.33
Breast lump with pain	03	3.33
Breast lump with discharge	02	2.22
Breast lump with abscess	01	1.11

Table 5: Distribution of cases according to histopathology of breast lesions:

Category	Diagnosis	No. of cases	Percentage (%)
Benign tumors	Fibroadenoma	53	58.88
	Benign Phyllodes tumour	01	1.11
	Fibroadenosis	04	4.44
	Lactating adenoma	01	1.11
	Tubular adenoma	01	1.11

	Lipoma	04	4.44
Malignant tumors	DCIS (Ductal carcinoma in situ)	04	4.44
	Invasive breast carcinoma, not otherwise specified	04	4.44
	Mixed ductal and lobular carcinoma	01	1.11
	Chronic mastitis	02	2.22
Non-neoplastic lesions	Duct ectasia	01	1.11
	Fat necrosis	01	1.11
	Fibrocystic disease	04	4.44
	Galactocele	01	1.11
	Gynecomastia	08	8.88

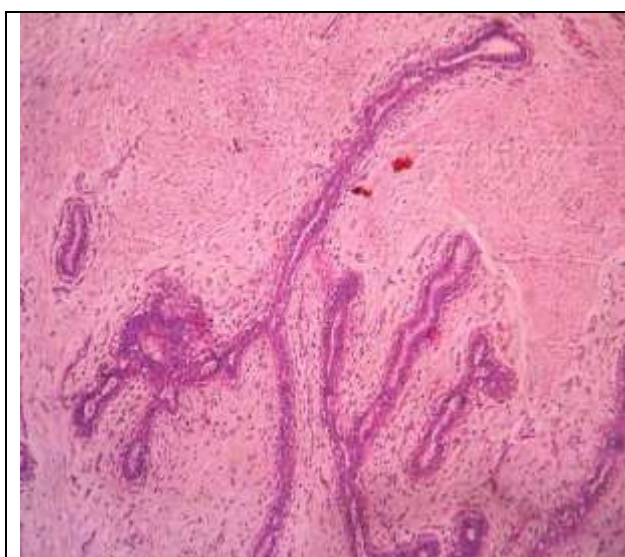


Figure 3: Fibroadenoma of breast

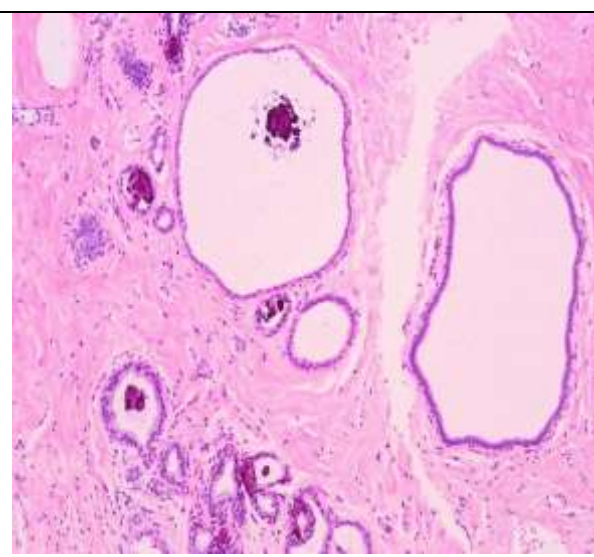


Figure 4: Fibrocystic disease of breast

DISCUSSION:

In present study, the most common age group affected was 21-30 years (37.77%), which correlate well with Honey Bhasker Sharma et al.^[8], Mrudula, et al.^[9], Yogalakshmi and Kavitha et al.^[10], Anushree C.N et al.^[11] and Rashmi Gupta et al.^[12]

In our study, 84 (93.33%) cases came to surgery OPD with complaint of breast lump only, which was similar to Yogalakshmi and Kavitha et al. study and Kiran H. S et al.^[13] In present study, only 2% cases had complaint of breast lump with discharge, Whereas in Yogalakshmi and Kavitha et al., it was found in 6% of cases.

In present study, out of 90 cases, 64 (71.11%) cases comprised benign breast lesions, while 9 (10%) cases were constituted by malignant lesions. This similar finding (Benign> malignant) was also highlighted by Honey Bhasker Sharma et al., Mrudula, et al., Yogalakshmi and Kavitha et al., Anushree C.N et al. and Rashmi Gupta et al. In benign lesions, fibroadenoma

was the most common cause, which was consistent with Honey Bhasker Sharma et al., Mrudula, et al., Yagalakshmi and Kavitha et al., Anushree C.N et al. and Rashmi Gupta et al., But these findings were differ with Kiran H. S et al., where incidence of malignant lesions (52%) were higher than the benign lesions (48%). And fibrocystic disease (41%) was the most common lesion followed by fibroadenoma (28%). In our study, malignant lesions like ductal carcinoma in situ (DCIS) and invasive breast carcinoma, not otherwise specified had similar incidence, which was 4.44%, in contrast Honey Bhasker Sharma et al., Mrudula, et al., Yagalakshmi and Kavitha et al., Anushree C.N et al. and Rashmi Gupta et al. found higher incidence of infiltrating duct carcinoma.

CONCLUSION:

In present study, benign breast lesions were the commonest breast diseases, in which fibroadenoma was the most common variety. Peak incidence of benign lesion found in the age group of 21-30 years. Right side of breast commonly involved by the breast lesions. Histopathology plays a key role in the early diagnosis and treatment of breast diseases.

REFERENCES:

1. Dr. Mayura Phulpagar, Dr. Rakesh Shedge, Dr. Darshana Wakkar. Study of Histomorphological Spectrum of Breast Diseases in a Tertiary care centre of Mumbai, Global Journal For Research Analysis 2018; 7 (6):65-67.
2. Klin TS, Neal Hs. Role of needle aspiration biopsy in diagnosis of carcinoma of breast. *Obstetrics & Gynaecology* 1975; 46:89-92.
3. Guray M. Benign Breast Diseases: Classification, Diagnosis, and Management. *The Oncologist*. 2006;11(5):435-449.
4. Dunn JM, Lucartti ME, Wood SJ, Mumford A, Webb AJ.: Exfoliative cytology in the diagnosis of breast disease. *British Journal of Surgery* 1995; 82: 789-91.
5. Nandakumar A: National Cancer Registry Programme- Consolidation reports of the population-based cancer registries, Indian council of Medical Research, New delhi 1990- 1998; [http:// icmr.nic.in/ncrp/HBCR2003.pdf](http://icmr.nic.in/ncrp/HBCR2003.pdf)
6. Kocjan G, Bourgain C, Fassina A, et al. The role of breast FNAC in diagnosis and clinical management: A survey of current practice. *Cytopathology* 2008; 19:271-8.
7. Akrami M, Mokhtari M, Tahmasebi S, Talei A. Surgical and Clinical Pathology of Breast Diseases. <http://www.dx.doi.org/10.5772/52105>.
8. Sharma H.B, Bansal M, Kumar N. Histomorphological spectrum of neoplastic and non-neoplastic breast lesions –A two year study in a teaching hospital of North India. *Arch Cytol Histopathol Res* 2018;3(4):181-184.
9. Mrudula, Spectrum of histopathological patterns of breast lesions in a tertiary care hospital. *Asian Journal of Medical Sciences*, 14(2), 151-156.
10. Yagalakshmi S, Kavitha M. A Study of Histopathological Spectrum of Breast Lesions. *Int J Sci Stud* 2019;7(1):1-5.
11. Anushree CN, Priyadarshini MR, Manjunatha YA. Histopathological spectrum of neoplastic and non-neoplastic lesions of breast in a tertiary care centre in Bangalore. *Indian J Pathol Oncol* 2019;6(2):203-6.

12. Rashmi Gupta et al (2022) 'Histopathological Spectrum of Breast Lesion In Tertiary Care Hospital, In Chhattisgarh Institute of Medical Sciences, Bilaspur, Chhattisgarh', International Journal of Current Medical and Pharmaceutical Research, 08(03), pp 86-88.

13. Kiran HS, Shetty J Rao C. "Histomorphological Spectrum of breast lesions". J Evolution Med Dent Sci 2016;5(54):3577-81.